

RIVA STAR AQUA, A NEXT GENERATION WATER BASED SOLUTION TO ARREST CARIES

AUTHOR:



DR VINICIUS MOREIRA

Dental Surgeon - Graduated from Universidade Paulista - UNIP, 2017. Taking a graduate course in odontopediatrics at Instituto Brasileiro de Pós Graduação IBPG/ FUNORTE - Brasília. Works as a general practitioner in the Goiás public service.

INTRODUCTION:

Cavities are considered the most common disease in childhood. As predictive factors, one could mention a diet high in fermentable carbohydrates, presence of bacteria in the dental biofilm, mouth hygiene habits, among others. When untreated, it can cause pain, dysfunction and even affect the performance of basic everyday activities.

With the progress of science, one of the dental cavity control agents that are proving most effective is Silver Fluoride [AgF] Riva Star Aqua, a product with preventive and cariostatic properties indicated for patients with high cavity risk and activity, common situations in odontopediatric practice.

The silver fluoride acts both in the inorganic portion of the dental structure and the organic portion, the sodium fluoride being responsible for the mineral part, which is hydroxyapatite, and the silver nitrate for the organic portion of proteins.

The reduction in the prevalence of cariogenic bacteria through cavity sealing and application of cariostatic agents is an important step that precedes the rehabilitating dental treatment. Therefore, the association between a cariostatic agent and an atraumatic restoring treatment is a therapeutic option of great value, especially in children with early childhood cavities.

The purpose of the report was to demonstrate carious lesion treatment with Riva Star Aqua[AgF].

CONCLUSION

The use of Riva Star Aqua 38% has demonstrated clinical success, being a technique specially used in the prevention and further progressing of carious lesions, facilitating the treatment of children and restoring health and function to deciduous teeth.

CASE REPORT

Patient: Male, 7 years, no systemic alterations and regular mouth health, accompanied by an adult responsible for him. During the medical history interview, the mother reported that the child had carious lesions in the front teeth which had increased, even having been restored a few times.

The physical exams found that molars 74 and 75 had active carious lesions with no pulp compromise (**Figure 1**). A treatment was planned with the family using SDI's cariostatic agent Riva Star Aqua [AgF] (**Figure 2**). The procedure was explained to the parents, including its benefits and an informed consent agreement was signed.

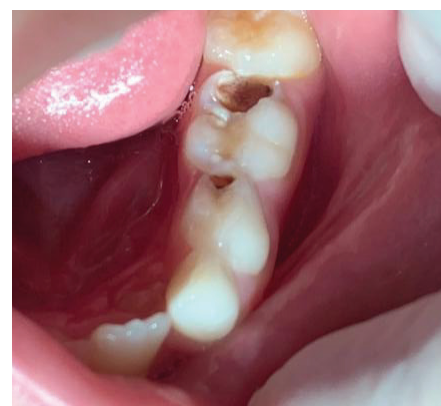

Figure 1 Prior to treatment



Figure 2 Riva Star Aqua [AgF]



Figure 3 Application of 1 drop of Riva Star Aqua Step 1

After prior cleaning, protecting the soft tissues with Vaseline and relative insulation with cotton. **Note:** Although Gingival protection is applied here, it is not necessary as there is no Ammonia in Riva Star Aqua that will irritate soft tissues.

Apply 1 drop of Riva Star Aqua (Step 1) with a point rubbing on teeth 74 and 75. Wait for 60 seconds (Figure 3 and 4).

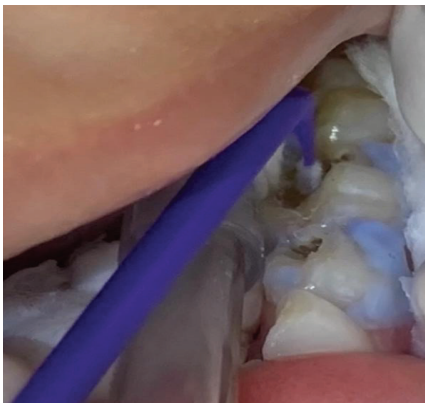

Figure 4 Product applied on tooth



Figure 5 Riva Star Step 2 - Potassium Iodide (KI)

After waiting for 60 seconds, apply the potassium iodide (Riva Star Step 2) with a new point, in a thin layer, repeating this process up to 5 times if necessary, to reduce the tooth's darkening effect (Figure 5 and 6). Remove the excess with absorbent paper and dry or clean abundantly in case the restoration has to be made in the same session.

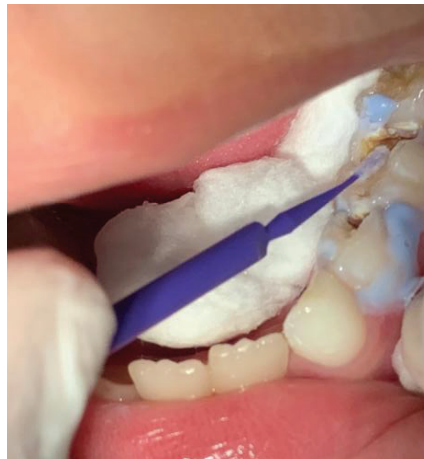

Figure 6 Application of 2 drops of Riva Star Step 2 (KI)

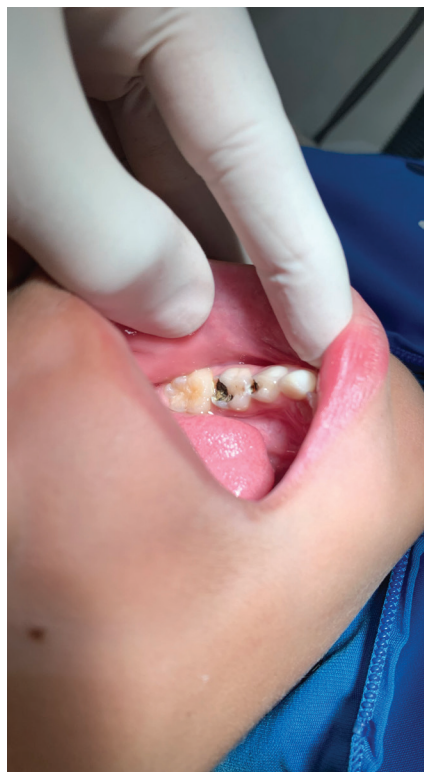

Figure 7 Results after 7 days' application and lesion halt.

Post verification of lesion halt, proceed to restoring of teeth 74 and 74 using Riva Self Cure.

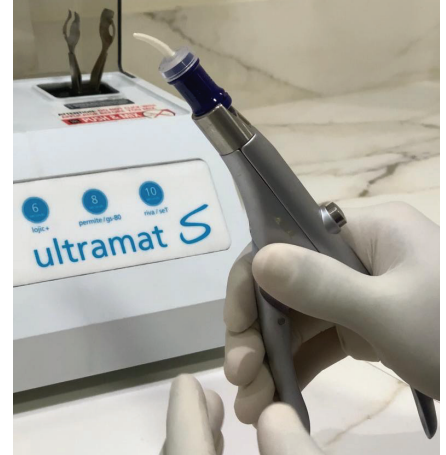

Figure 8 Handling of Riva Self Cure

Mix the Riva Self Cure on Ultramat for 10 seconds. Insert the capsule in Riva Applicator (Figure 8) and apply Riva Self Cure in the cavity (Figure 9). With the spatula, remove the excess material and shape it. Adjust and protect the ionomer and finish restoring teeth 74 and 75 (Figure 10).

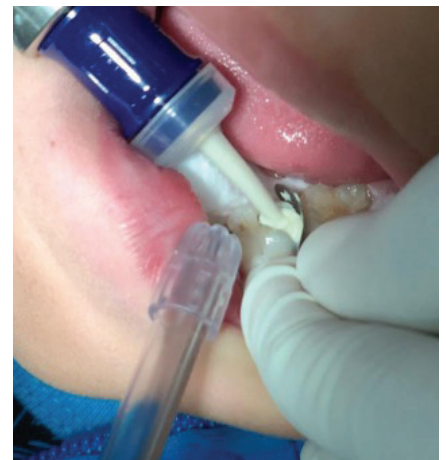


Figure 9 Application of Riva Self Cure in the cavity

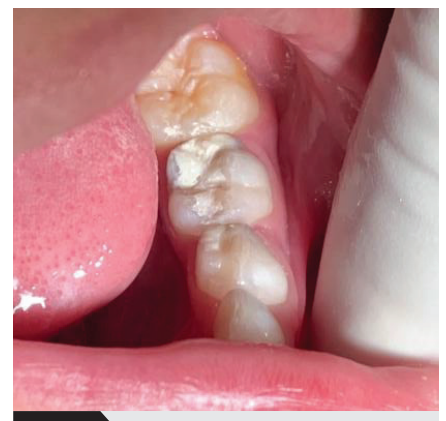

Figure 10 After treatment with Riva Star Aqua and Restoring with Riva Self Cure (GIC)

REFERENCES

- 1.. Rocha C, Miasato JM, Farinhas J, Schuller AF. Diamino fluoreto de prata: uma opção em odontopediatria. JBP, j bras. Odontopediatr. Odontol. Bebê 1999; 2(8):296-301.
2. Juliana da Silveira GAIOTTO, Rafael Amorim MARTINS, Angela Cristina Cilense ZUANON. Uso do diamino fluoreto de prata [DFP] no atendimento odontopediátrico. Rev. odontol. UNESP, vol.49, n Especial, p.155, 2020.
3. RUSSO, M.; TOMATSU, J.; TAKAYAMA, S.; HOLLAND JÚNIOR, C.; SUNDFELD R. H.; CASTRO, M. A. M.; QUINTELLA L. P. A. S.; MESTRENER S. R. Efeitos da aplicação da solução de Diamino fluoreto de prata a 38% em dentina de dentes decíduos de cães. Revista Brasileira de Odontologia, v. 43, n. 2, p. 14-19, 1986.

PRODUCTS USED



CLINICAL CASE 2023.014